


## TSE06 –OV negative

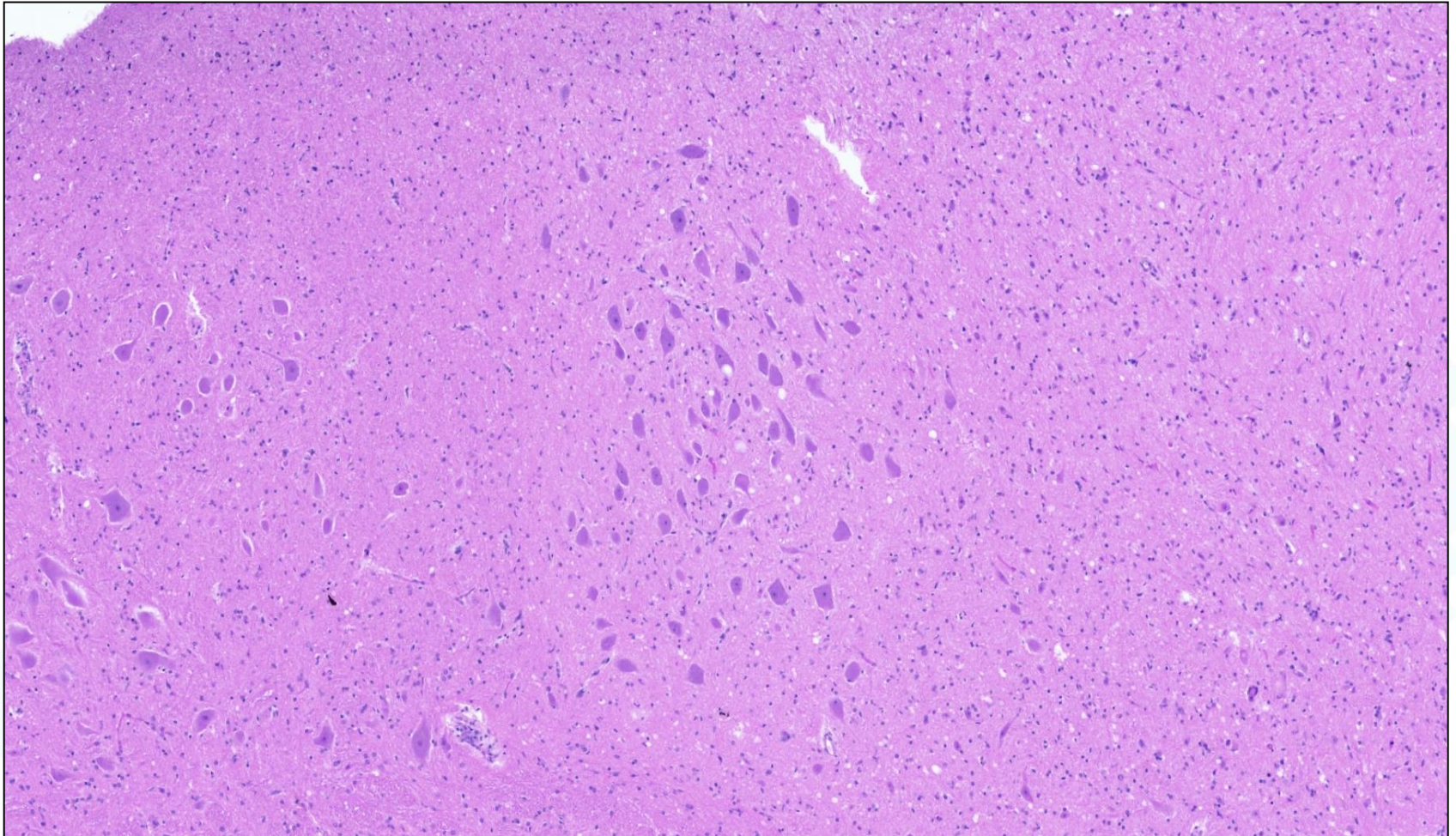


TSE EURL

Istituto Zooprofilattico Sperimentale del Piemonte, Liguria e Valle d'Aosta – Turin  
Istituto Superiore di Sanità - Rome




## TSE08 –OV positive



TSE EURL

Istituto Zooprofilattico Sperimentale del Piemonte, Liguria e Valle d'Aosta – Turin  
Istituto Superiore di Sanità - Rome

## TSE09 –OV negative

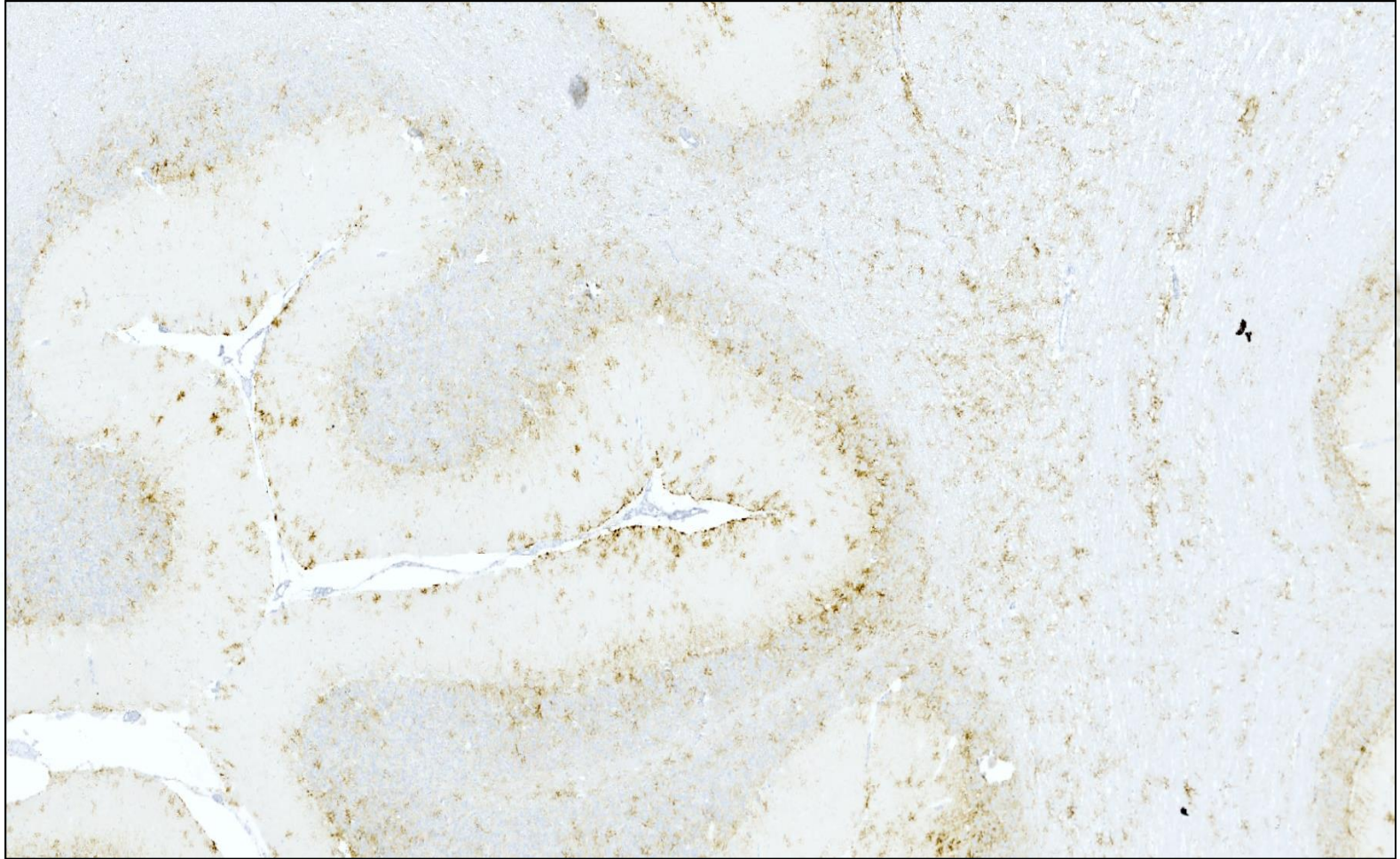


TSE EURL

Istituto Zooprofilattico Sperimentale del Piemonte, Liguria e Valle d'Aosta – Turin  
Istituto Superiore di Sanità - Rome



## TSE12-OV Classical

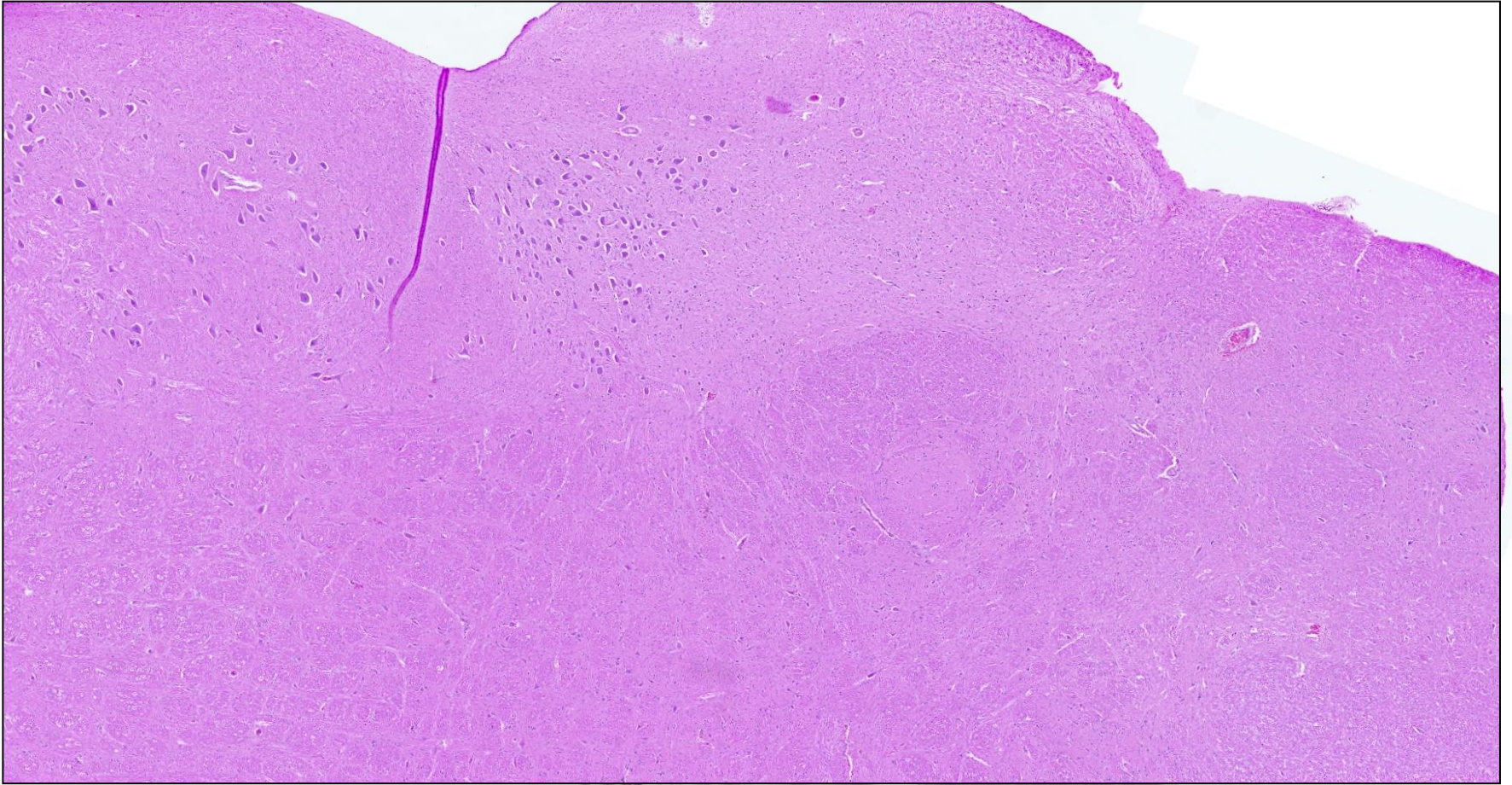


TSE EURL

Istituto Zooprofilattico Sperimentale del Piemonte, Liguria e Valle d'Aosta – Turin  
Istituto Superiore di Sanità - Rome



## TSE14 –BV negative




IURL TSE

Istituto Zooprofilattico Sperimentale del Piemonte, Liguria e Valle d'Aosta – Turin  
Istituto Superiore di Sanità - Rome



## TSE15 –OV Atypical



# Histopathology interpretation - Conclusion

The EURL Histopathology interpretation has achieved good results.

There were only two serious errors.

Some readers have had difficulty distinguishing between classical and atypical scrapie.

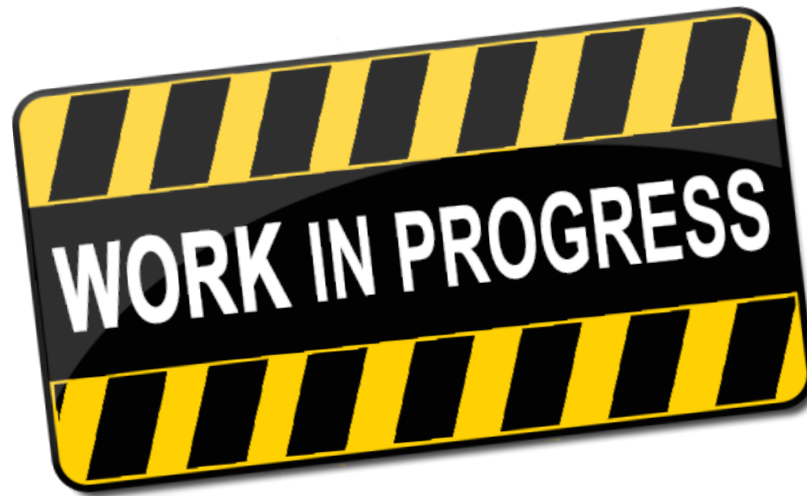

TSE EURL

Istituto Zooprofilattico Sperimentale del Piemonte, Liguria e Valle d'Aosta – Turin  
Istituto Superiore di Sanità - Rome

# PrP IHC EQA 2020

We are working to organize the  
Histopathology interpretation  
2021 that will be in December



TSE EURL

Istituto Zooprofilattico Sperimentale del Piemonte, Liguria e Valle d'Aosta – Turin  
Istituto Superiore di Sanità - Rome



# THANK YOU FOR YOUR ATTENTION

Dr.ssa Barbara Iulini/Cristina Casalone

SS Neuropatologia

Tel +39011- 2686261 -296

e-mail [barbara.iulini@izsto.it](mailto:barbara.iulini@izsto.it); [cristina.casalone@izsto.it](mailto:cristina.casalone@izsto.it)



TSE EURL

Istituto Zooprofilattico Sperimentale del Piemonte, Liguria e Valle d'Aosta – Turin  
Istituto Superiore di Sanità - Rome